

# 10

# Identification of complete denture problems: a summary

J. F. McCord,<sup>1</sup> and A. A. Grant,<sup>2</sup>

**In this section, guidelines to the diagnosis of complete denture problems are presented in tabular form. Suggestions to the management of these problems are listed.**

**In this part, we will discuss:**

- Factors resulting in discomfort associated with dentures
- Factors resulting in looseness of the dentures
- Factors associated with problems of adaptation

<sup>1</sup>Head of the Unit of Prosthodontics,  
<sup>2</sup>Emeritus Professor of Restorative Dentistry, University Dental Hospital of Manchester, Higher Cambridge Street, Manchester M15 6FH

\*Correspondence to: Prof. J. F. McCord  
email: Learj@fs1.den.man.ac.uk

REFEREED PAPER

© British Dental Journal  
2000; 189: 128–134

There is, inevitably, the potential for problems to arise subsequent to the insertion of complete dentures. These problems may be transient and may be essentially disregarded by the patient or they may be serious enough to result in the patient being unable to tolerate the dentures.

Factors causing problems may be grouped, essentially into four causes.

- Adverse intra-oral anatomical factors eg atrophic mucosa.
- Clinical factors eg poor denture stability.
- Technical factors eg failure to preserve the

Table 1 List of factors resulting in discomfort related to the impression surface of dentures		
Symptoms/clinical findings	Cause	Treatment
Related to impression surface Discrete painful areas	Pearls or sharp ridges of acrylic on the fitting surface arising from deficiency in laboratory finishing	Locate with finger, or snagging dry cotton wool fibres. Use disclosing material to assist locality to ease denture
Pain on insertion and removal, possibly inflamed mucosa on side(s) of ridges	Denture not relieved in region of undercuts	Use disclosing material to adjust in region of 'wipe off'. Exercise care as excessive removal may reduce retention. Also clinician should only insert denture and then remove it - the patient should not occlude as this may confuse an occlusal fault with support problems
Areas painful to pressure	Pressure areas resulting eg from faulty impressions, damage to working cast, warpage of denture base. Consider also residual pathology (eg retained root), lack of relief for active frena, non-displaceable mucosa over bony prominence (eg torus)	Use disclosing material to accurately locate area to be relieved. If severe, remake may be required. Consider removal of root
Over-extension of lingual flange. Painful mylohyoid ridge; denture lifts on tongue protrusion; painful to swallow	Over-extended lower impression: instructions to laboratory not clear or non-existent	Determine position and extent of over-extension using disclosing material and relieve accordingly
Generalised pain over denture-supporting area	Under-extended denture base - may be the result of over-adjustment to the periphery, or impression surface. Check for adequacy of FWS	Extend denture to optimal available denture support area. If insufficient FWS, remake may be required
Lack of relief for frena or muscle attachments; pinching of tissue between denture base and retromolar pad or tuberosity. Sore throat, difficulty in swallowing	Peripheral over-extension resulting from impression stage and/or design error. Palatal soreness as post dam too deep	Relieve with aid of disclosing material. Care with adjustment of post dam - removal of existing seal and its replacement in greenstick prior to permanent addition may be required

Table 2 List of factors resulting in discomfort - relating to occlusal and polished surfaces of dentures		
Symptoms/clinical findings	Cause	Treatment
<i>Related to occlusal surfaces</i> Pain on eating in presence of occlusal imbalance (no support problems)	Anterior prematurity or posterior prematurity, incisal locking, lack of balanced articulation	Determine where occlusal prematurities exist. Adjust occlusion by selective grinding. If severe error remount using facebow and new interocclusal records
Pain lingual to lower anterior ridge	If no over-extension present, look for protrusive slide from RCP to ICP	Mark deflecting inclines of posterior teeth with thin articulating paper. If slide exceeds half a cusp width, re-register and reset
Pain and/or inflammation on labial aspect of lower ridge	If no impression surface defect, may be lack of incisal overjet causing incisal locking	Reduce incisal vertical overlap. If appearance compromised, resetting the incisors may be required
Pain about periphery of dentures possibly accompanied by pain in masseter and posterior temporalis muscles (classically pain increases as the day progresses)	Vertical dimension of occlusion more than patient can tolerate	If excess less than 1.5 mm, grind to provide FWS. If greater than 1.5 mm, re-register to reset dentures at new OVD
Cheek and or lip biting	For cheeks - likely that functional width of sulcus was not restored. For lips - poor lip support/inadequate anterior horizontal overlap	For cheek biting, restore functional width of sulcus and/or reset. For lips, grind lower incisors to provide a more appropriate incisal guidance angle
Tongue biting	Lack of lingual overjet - teeth generally placed lingual to lower ridge	Remove lower lingual cusps, or reset teeth
<i>Related to polished surfaces</i> Pain at posterior aspect of upper denture on opening	Flange on buccal aspect of tuberosity too thick and constraining coronoid process	Use disclosing material to accurately define area involved, relieve and repolish

- peripheral roll on a master cast.
- Patient adaptational factors.

By far the most critical factors are the patient adaptational factors. Many patients with positive stereotypes may overcome errors of prescription. Some patients, however, are unable to adapt physically and/or psychologically to dentures that satisfy clinical and technical prosthodontic norms. Clearly it would be in the best interests of the clinician and the patient to determine this at the assessment stage, and was referred to in Part 2.

The prescribing clinician is responsible for planning complete dentures after diagnosing potential problems; be they anatomical, physiological, pathological or emotional.

Once a denture-wearing problem becomes apparent, it is important that it is addressed in

a logical and systematic way. That is to say, an adequate history of the problem must be obtained and a careful examination of the mouth carried out so that an accurate diagnosis can be made, and an appropriate treatment plan devised.

Without doubt listening to the patient (as their difficulties are described) is the most important first step in the process, and its importance cannot be overemphasised.

Because of the plethora of potential complete denture problems, this section is largely confined to those that are most commonly encountered at the time of insertion of replacement dentures or during review appointments in the days and weeks after insertion. For a comprehensive overview of the diagnosis and management of complete denture problems, readers are referred to

<b>Table 3</b> List of factors resulting in discomfort - factors with possible systemic associations. Some of these conditions may occur several months post insertion		
Symptoms/clinical findings	Cause	Treatment
Burning sensation over upper denture supporting tissues, but may involve other intra-oral tissues, eg tongue.	Burning mouth syndrome often seen in middle-aged or elderly females. Denture faults must be excluded, also general organic and psychogenic factors	Correction of any denture faults, may require multivitamin/nutrition advice and treatment. Possibly antidepressant therapy. Refer to Consultant in Oral Medicine
Beefy red tongue, possibly glossodynia	Vitamin B12/folate deficiency	Refer for medical treatment
Frictional lesions related to dentures, mucosa may adhere to probing finger, may be complaint of dry mouth	Xerostomia, commonly side effect of prescribed drugs	Where some saliva flow is present, sugar-free citrus lozenges may help. Where there is an obvious paucity of saliva, artificial saliva may be considered
Tongue thrusting. Empty mouth 'chewing'. Often seen in elderly patients	May have neurological or psychological aspects. Possibly drug related	Difficult to manage. Treatment may be required to include occlusal adjustment and/or occlusal pivots
Presence of herpetiform ulcers in mouth	Herpes simplex or Herpes zoster virus. History and distribution of lesions to confirm	Dentures merely coincidental to the condition. May be useful to suggest preventive remedy (eg acyclovir) for some sufferers
Painful 'click' related to TMJ on opening and/or closing mouth and/or tenderness of muscles of mastication	TMJ pain dysfunction syndrome may be related to rapid change on OVD (either gross increase or decrease) on production of new denture. May have psychological aspects, occasionally part of general joint disease	If denture faults present, careful correction required with special care to registration and vertical dimension
Patient complains of allergy to denture material	Rare symptoms may relate to higher residual monomer content of acrylic	If excess residual monomer detected, rebase denture using controlled heat cure cycle. May need to consider remaking denture using polycarbonate resin
Painless erythema of mucosa related to support of (usually) upper denture, may be accompanied by angular cheilitis	Denture-related stomatitis. Often has a frictional element due to ill-fitting denture plus opportunistic candidal infection. Occasionally related to iron or folate deficiency	Best to leave denture out until condition clears, then remake. If not possible, correct denture faults, eg using occlusal pivots, regularly supervised and replaced tissue conditioners prior to remake. If angular cheilitis present, combinations of antifungal and antibacterial agents (eg miconazole) useful

standard prosthodontic texts.

Problems reported by patients shortly after provision of replacement dentures include discomfort, looseness or general problems in relation to adaptation. Some of these problems/difficulties may have a very large number of possible causes, and, indeed, can be multifactorial in origin. For simplicity the problems will be discussed in the order they tend to occur most frequently.

In the following tables, a list of causes and suitable forms of treatment to address the problems are summarised.

**Discomfort associated with dentures**

Many patients experience some discomfort for a period of up to a few days following receipt of new or replacement dentures. The great majority of patients achieve comfortable co-existence with their appliances following a short period of adjustment to the new conditions. This can be greatly assisted by a careful, detailed explanation of any difficulties that the operator might anticipate.

For some, however, especially where potential problems were not identified at examination or at the time of insertion, the consequent

Table 4 List of factors resulting in looseness of dentures - arising from decreased retention forces		
Symptoms/clinical findings	Cause	Treatment
Lack of peripheral seal	<p>Border under-extension in depth</p> <p>Border under-extension in width. Often a particular problem in disto-buccal aspects of upper periphery which may be displaced by buccinator on mouth opening.</p> <p>Posterior border of upper denture</p>	<p>Add softened tracing compound to relevant border, mould digitally and by functional movements by patient. Replace compound with acrylic resin. As a temporary measure a chairside reline material may be used as described above</p> <p>Check border is correctly sited on fixed tissue at junction with mobile tissue of soft palate. Trace thin string of softened tracing compound along impression surface of posterior border and seat denture firmly in mouth. Replace compound with acrylic resin. For temporary solution, use butymethacrylate resin as above</p>
Inelasticity of cheek tissues	Consequence of ageing process; scleroderma, submucous fibrous	Mould denture borders incrementally using softened tracing-compound as functional movements are performed - aim to slightly under-extend depth and width of denture periphery. Repeated treatment may be required as inelasticity progresses
Air beneath impression surface. Denture may rock under finger pressure. May see gap between periphery of flange and ridge. Occlusal error subsequent to warpage	Deficient impression. Damaged cast. Warped denture. Over-adjustment of impression surface. Residual ridge resorption. Undercut ridge. Excessive relief chamber. Change in fluid content of supporting tissues	Reline if design parameters of denture satisfactory, otherwise remake as required. Ensure that areas of heavy contact between denture and tissues are relieved prior to impression making. Where change in tissue fluid distribution is suspected check medication (eg diuretics) posture (eg heart failure) lack of recovery of tissues from effects of old denture prior to working impressions being obtained. Stabilise fluid content of tissues and use minimal pressure impression method
Xerostomia Reduces ability to form a suitable seal	Medication by many commonly prescribed drugs, irradiation of head and neck region, salivary gland disease	Design dentures to maximise retention and minimise displacing forces. Prescribe artificial saliva where appropriate
Neuromuscular control Essential for successful denture wearing: speech and eating difficulties occur	Basic shape of denture incorrect, lower molars too lingual; occlusal plane too high: upper molars buccal to ridge and buccal flange not wide enough to accommodate this; lingual flange of lower convex. Patient of advanced biological age, infirm	Correct design faults by, eg removal of lingual cusps of posterior teeth. Flatten polished lingual surface of lower from occlusal surface to periphery, fill sulci to optimal width. May require remake to optimal design. Use information from successful previous denture if available. Denture adhesives may be deemed to be necessary

discomfort can be prolonged.

In addition, discomfort may arise some time after apparently successful prosthodontic provision as a result of intra-oral or systemic changes or of denture wear or damage. Discomfort is most frequently—but not exclusively—associated with the lower denture supporting area.

The Tables (Tables 1, 2 and 3) summarise commonly experienced sources of discomfort, and means of addressing the causative factors.

### Looseness of dentures

Looseness of dentures (Tables 4, 5 and 6) is more commonly associated with the lower denture, and may be referred to by patients as their denture ‘rocking’, ‘falling’ (complete upper) or ‘rising’ (complete lower), ‘shifting’ or sometimes that they ‘feel too big’.

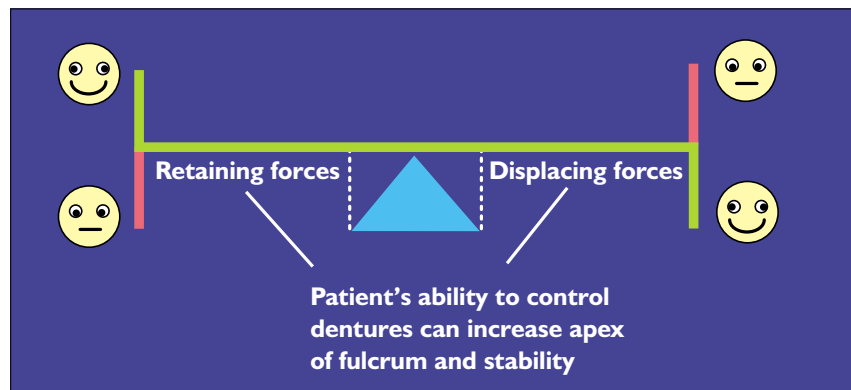
In simple terms, retention and stability of complete dentures may be likened to a simple balance ie on one side retaining forces and on the other displacing forces. If the latter exceed the former, instability/looseness will arise. It

Table 5 List of factors resulting in looseness of dentures: arising from increased displacing forces		
Symptoms/clinical findings	Cause	Treatment
<i>Denture borders</i> <i>Over-extension in depth</i> Slow rise of lower denture when mouth half open, line of inflammation at reflection of sulcal tissues; ulceration in sulcal region. Deep post dam on upper base may cause pain, ulceration	If buccal to tuberosities, denture displaces on mouth opening, or cheek soreness occurs. Thickened lingual flange enables tongue to lift denture; thick upper and lower labial flanges may produce displacement during muscle activity	Slightly under-extend denture flange and accurately mould softened tracing compound. Check borders of record rims and trial dentures at the appropriate stages. Deep post dam to be cautiously reduced and denture worn sparingly until inflammation clears
<i>Overextension in width</i> Cheeks appear plumped out. In lower, the buccal flange may be palpated lateral to external oblique ridge	Design error	Reduce over-extension. Use disclosing material to determine what is excessive
<i>Poor fit to supporting tissue</i> Recoil of displaced tissue lifts denture	Poor/inappropriate impression technique especially in posterior lingual pouch area	Reline if all other design parameters satisfactory, otherwise remake. Ensure denture is removed from mouth 90 mins prior to impression
Denture not in optimal space	Molars on lower denture lingual to ridge, optimum triangular shape of dentures absent  Posterior occlusal table too broad, causing tongue trapping  Thick lingual flanges encroaching on tongue space, causing lifting. Excess lip pressure to lower anterior aspect - teeth anterior to ridge, thick periphery Excess pressure from upper lip to upper denture arising from teeth too labially sited to acute naso-labial angle; or failure to adequately seat denture during relining impression procedure	Remove lingual cusps and lingual surface from relevant area, repolish. If triangular form not restored, reset teeth or remake dentures Narrow posterior teeth and/or remove most distal teeth from dentures. Reshape lingual polished surface Thin lower labial flange, ensure optimal extension to retromolar pads to resist displacement, reset anterior teeth if necessary Usually requires remaking denture

must be stressed, however, that the fulcrum is the patient, or rather the patient's ability to adapt to dentures — this is less easy to anticipate. This is illustrated in Figure 1, which is a line drawing of factors influencing complete denture stability.

**Problems relating to an inability to adapt to dentures**

There are a variety of symptoms which may be functionally-related (ie eating associated prob-



**Fig. 1 Factors influencing complete denture stability**

Table 6 List of factors resulting in looseness of dentures - arising from increased displacing forces - occlusal and anatomical factors		
Symptoms/ clinical findings	Cause	Treatment
Occlusal errors	<p>Uneven tooth contact causing tilting of dentures and prevents even seating of loosened appliances</p> <p>ICP and RCP not coincident - disrupts border seal and prevents accurate reseating</p> <p>Lack of freedom in ICP (occlusal-locking) dentures will shift on supporting tissues for those patients with poor control of mandibular movements</p>	<p>Adjust occlusion until even initial contact in RCP obtained. If gaps between teeth exceeds 1.5 mm reset teeth or remake dentures. For gaps less than 1.5 mm it may still be necessary, in the interest of accurate diagnosis, to remount the dentures, as a patient's mouth may be too tender to permit chairside adjustment. Adjust occlusion for coincident ICP/RCP contact. If error is greater than half width of cusp, all teeth on at least one denture need resetting.</p> <p>Remount dentures on adjustable articulator and adjust area of occlusal contact. Allow 1.5 mm of anterior movement from RCP. May use cusplless teeth where appropriate</p>
Ulceration labial to lower ridge	<p>Excessive vertical overlap of anterior teeth. Lack of balance and anterior tooth contact may cause tilting, soreness in lower ridge</p> <p>Last mandibular molars placed too far posteriorly and lie over retromolar pad or ascending part of ramus. Occlusal contact on this 'inclined plane' causes denture to slip forward</p> <p>Occlusal plane/s not orientated appropriately and masticatory forces tend to move dentures over supporting tissues</p>	<p>Reduce height of lower anteriors. Aesthetic problems may necessitate resetting of teeth</p> <p>Remove most posterior teeth from denture</p> <p>Usually requires teeth to be reset or dentures to be remade</p>
Fibrous displaceable ridge	Masticatory forces tend to cause denture to sink into and tilt towards supporting tissues	Reline after removal of acrylic from impression surface until no contact with displaceable tissue, provide many vent holes, low viscosity impression material, maximise posterior border seal
Bony prominence covered by thin mucosa (eg tori)	Denture rocks over prominence which may be covered with inflamed tissue	Remove acrylic from impression surface where disclosing material shows excessive loading of supporting tissues. Do not create excessive relief or loss of retention may result
Non-resilient soft tissue	Does not adapt to impression surface of denture reducing support and retention factors	Reline dentures to obtain optimal border extensions in depth and width, use low viscosity impression material
Pain avoidance mechanisms	Use of excessive amounts of fixative, or self-applied reline material, or even cotton wool, to attempt to relieve contact with supporting tissues	Eliminate the cause of pain

lems, speech etc), psychologically-related or may relate to patience. Clearly there is a need to diagnose the former at the planning stage of treatment and to avoid the latter by virtue of trial denture visits which focus on the functional and aesthetic components of the compete dentures.

Some of the psychologically-related problems may be recognised at an early stage but even if psychological assessments are taken, not all are infallible.

A brief list of factors affecting adaptation to dentures including their causes and modes of treatment are listed in Table 7.

### Summary

This chapter has attempted to summarise in a tabular form a list of factors that are commonly found at recall visits. The tables themselves are self-explanatory and serve as a 'useful tip' list.

For more detailed lists, readers are referred to standard prosthodontic text.

Table 7 List of denture problems associated with problems of adaptation		
Symptoms/clinical findings	Cause	Treatment
Noise on eating/speaking May be apparent on first insertion or may appear as resorption causes dentures to loosen	May be lack of skill with new dentures, excessive OVD, occlusal interference, loose dentures, or poor perception of patient to denture wearing	Where unfamiliarity present, reassurance and persistence recommended. Address specific faults or remake as required
Eating difficulties Dentures move over supporting tissues	Unstable dentures. Check that retentive forces are maximised and displacing forces minimised and all available support has been used	Construct dentures to maximise retention and minimise displacing forces
'Blunt teeth'	Broad posterior occlusal surfaces which replaced narrow teeth on previous denture. Non anatomical type teeth used where cusped teeth previously used	Where non-anatomical teeth used, careful explanation of rationale is required, may be possible to reshape teeth. Routine use of narrow tooth moulds recommended.
'Jaws close too far'	Lack of OVD, so that mandibular elevator muscles cannot work efficiently	May increase up to 1.5 mm by relining but if deficiency is greater, remake denture
'Cannot open mouth wide enough for food'. May be speech problems and facial pain especially over masseter region	Excessive OVD	Can remove up to 1.5 mm from occlusal plane by grinding, but if more is required, remake dentures
Speech problems Uncommon, but presence is of great concern to patient. May affect sibilant (eg s), bilabial (eg p,b), labiodental (eg f.v)	Cause may not be obvious. May be unfamiliarity - check that problem not present with old dentures	Check for vertical dimension accuracy, and that vertical incisor overlap not excessive. Palatal contour should not allow excessive tongue contact or air leakage - assess using disclosing paste over denture palate while sound is made. NB It is recommended that the patient's speech is assessed at trial insertion visit
Gagging May be volunteered by patient prior to treatment, or apparent at commencement of treatment or on insertion of denture	May be loose dentures, thick distal border of upper denture: lingual placement of upper posterior teeth or low occlusal plane causing contact with dorsal aspect of tongue	Construct dentures to maximise retention and minimise displacing forces. Use 'condition' appliance eg fully extended base for home use. Psychological assessment if indicated
Appearance Complaints may arise from patient or relatives. Common complaints include: shade of teeth too light or dark; mould too big/small; arrangement too even or irregular or lacking diastema	Patient failed to comment at trial stage, or has subsequently been swayed by family or friends. Perhaps the change from the old denture to the replacement denture is too sudden/severe	Accurate assessment of patient's aesthetic requirements. Ample time for patient comments at trial stage. Use any available evidence to assist - photographs, previous dentures. Consider template prosthesis
Too much visibility of teeth	Level of occlusal plane unacceptable, teeth placed on upper anterior ridge and no/poor lip support	Accurate prescription to laboratory via optimally adjusted occlusal rim
Creases at corners of mouth	Labial fullness and anterior tooth position may be inaccurate. OVD may be inadequate	Adjust tooth position as appropriate. If OVD problem, re-register jaw relations
Colour of denture base material 'unnatural'	Patient's skin colour not taken into account in determining colour of base material	Remake using suitable base material